

# Ruddy Turnstone retains egg in oviduct for five months

PHIL F. BATTLE<sup>1</sup>, WOUTER K. VAHL & BERNARD SPAANS

Department of Marine Ecology and Evolution, Royal Netherlands Institute for Sea Research (NIOZ),  
PO Box 59, 1790 AB Den Burg, Texel, The Netherlands

Battle, P.F., Vahl, W.K. & Spaans, B. 2003. Ruddy Turnstone retains egg in oviduct for five months. *Wader Study Group Bull.* 101/102: 67–69.

A Ruddy Turnstone caught in The Netherlands in September 2002 and held in captivity for feeding experiments was euthanased in mid-November, after concern about what appeared to be a solid growth in its abdomen. A necropsy revealed that the bird was egg-bound, with a large, soft-shelled egg at the distal end of its oviduct. The egg+oviduct mass of 16.5 g constituted 14.9% of the bird's body mass (110.8 g). As the average start of egg-laying in the Baltic region is from the end of May to mid-June, it is likely that this bird had been carrying the egg matter for around five months. While egg-binding is often fatal to birds, this is clearly not always the case. However, unlike 17 other Turnstones caught in October 2002 the bird had performed no pre-basic moult and had extremely worn plumage. The bird presumably suffered secondary infections as a result of egg-binding. Carrying an extra 15.7–18.6% of the "egg-free" body mass may have imposed a transport cost.

## INTRODUCTION

As part of studies on interference in foraging waders, W.V. and B.S. brought 18 Ruddy Turnstones *Arenaria interpres* into captivity in September–October 2002. Birds were caught at night by mist-net in the western (1 bird, 27 September) and eastern (17 birds, 8 October) parts of the Dutch Wadden Sea and were held at the experimental shorebird facilities at the Royal Netherlands Institute for Sea Research, Texel, The Netherlands. In captivity, birds were trained to eat maggots (Diptera larvae) and to feed on periodically available feeding-flats.

Concerns were raised for one bird when we realised that it had a hardened abdomen, the cause of which was not clear. Moreover the bird's plumage was in poor condition, suggesting that it might not have been producing preen waxes. The bird was euthanased on 13 November 2002 to determine the cause of the swollen abdomen (particularly to discover whether the apparent problem had been induced by conditions in captivity). In this note, we compare the body mass and moult status of this individual ("individual one") with the rest of the captive Turnstones, and describe the unexpected necropsy results, that the bird still had an egg in its oviduct, roughly five months after the main Turnstone laying period.

## SAMPLES AND OBSERVATIONS

### Source of birds, body masses and moult

Most Turnstones in the study were caught by the ringing group Stichting Calidris and W.V. at Schiermonnikoog (53°28'N, 06°15'E) in the eastern Dutch Wadden Sea (Table 1). Individual one was the only bird caught (by W.V. and B.S.) along the dike at Den Helder in the western Wadden Sea (52°57'N, 04°43'E). Birds were weighed ( $\pm 0.1$  g) on an electronic bal-

ance, and the extent of the pre-basic (post-breeding) moult was assessed by scoring different feather tracts in the body as old, moulting or new. Scores were summarised for the flight feathers (primaries, secondaries and tertials) and for contour feathers (mantle, breast, upperwing coverts) such that an overall score of "old" or "new" means all feather groups were that category, while "moulting" means that one or more groups were in moult. Individual one was the heaviest bird at capture (117.2 g compared with an average of 88.5 g for the other birds), but was the only bird that had not moulted any of its flight or contour feathers (Table 1).

### Necropsy results

The cause of the abdominal swelling was easily identified as an egg in the lower oviduct adjacent to the cloaca (Fig. 1). The egg was approximately 29 × 31 × 24 mm in size, with no hardened shell. The egg contents were largely solid and yellowish, though a small amount of yellow material was still semi-liquid. There was a "vein" of dark material running down the centre of the egg. The contents had an unpleasant odour. The oviduct was convoluted, thick and hardened, with an average width of 4.8 mm (mean of seven measurements along length). At the proximal end of the oviduct, a separate thickened part was separated from the rest of the thickened oviduct by a small length of "typical" thin oviduct only about 1 mm thick (L-shaped, 13.7 mm × 13.0 mm along the arms, 8.0 mm deep). One loose white "ball" 4.0 mm across may have been another egg follicle. The follicles at the ovary itself were all 0.5 mm or less in diameter (typical for northern-hemisphere waders in the non-breeding season). The egg weighed 11.3 g, while the rest of the oviduct weighed 5.2 g. 16.5 g of the total body mass of 110.8 g (14.9%) consisted of reproductive material.

<sup>1</sup> Department of Mathematics and Statistics, University of Otago, PO Box 56, Dunedin, New Zealand,  
e-mail: philbattle@quicksilver.net.nz

\* Corresponding author



**Table 1.** Capture and biometric characteristics of Ruddy Turnstones brought into captivity at the NIOZ in September–October 2002. Birds were caught at Den Helder (site 1) or Schiermonnikoog (site 2). Old and new feathers correspond to summer and winter plumage respectively (see text for more details).

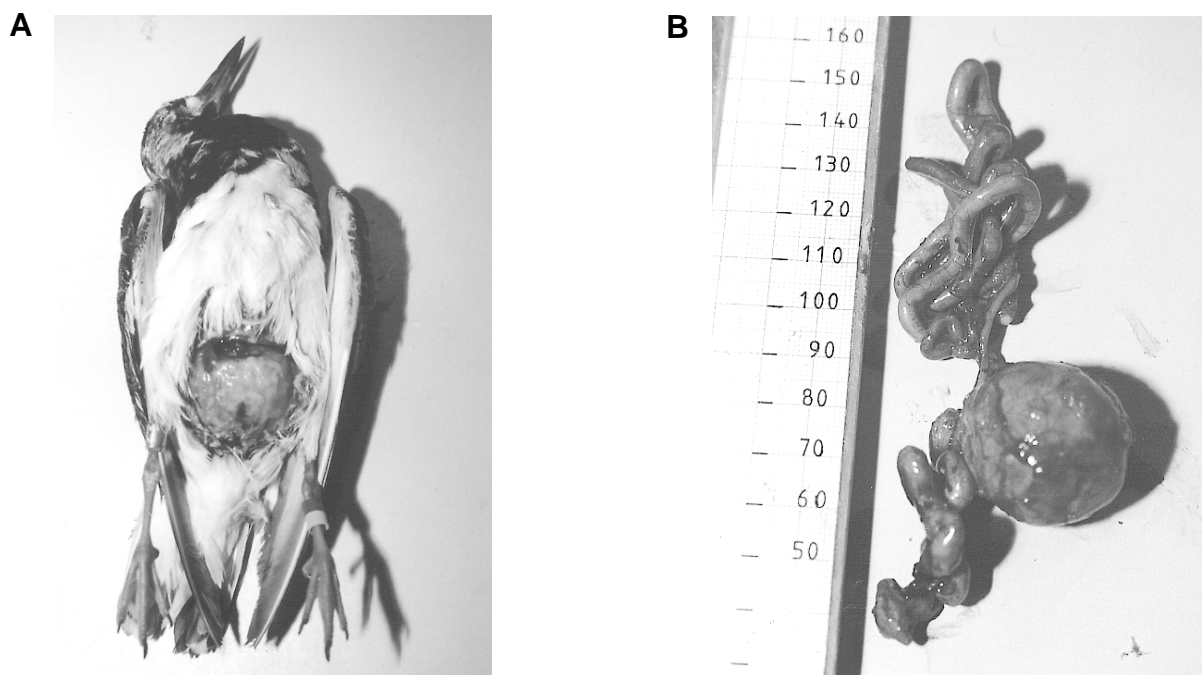
Individual	Site	Date	Mass (g)	Moult status	
				Flight	Contour
1	1	27-09	117.2	old	old
2	2	08-10	97.3	moulting	moulting
3	2	08-10	92.8	old	moulting
4	2	08-10	88.8	moulting	moulting
5	2	08-10	82.9	moulting	moulting
6	2	08-10	85.2	new	moulting
7	2	08-10	95.0	moulting	new
8	2	08-10	90.0	moulting	moulting
9	2	08-10	98.5	moulting	moulting
10	2	08-10	83.1	new	moulting
11	2	08-10	77.2	old	moulting
12	2	08-10	97.0	new	moulting
13	2	08-10	91.9	moulting	moulting
14	2	08-10	78.0	moulting	new
15	2	08-10	75.5	new	moulting
16	2	08-10	92.4	moulting	moulting
17	2	08-10	87.5	new	moulting
18	2	08-10	91.3	new	moulting

### Body mass changes over time

Knowing the mass of reproductive material in individual one's abdomen, we can compare total body mass and "equivalent" body mass without the egg mass over the period of the experiment (9 October to 11 November; Fig. 2). The mass of individual one tracked the changes in the group as a whole, but while the total body mass was one of the heaviest in the group, the mass without reproductive material was generally at the lower end of the range. The egg mass added an extra 15.7–18.6% to the total "egg-free" mass over the period covered in Fig. 2.

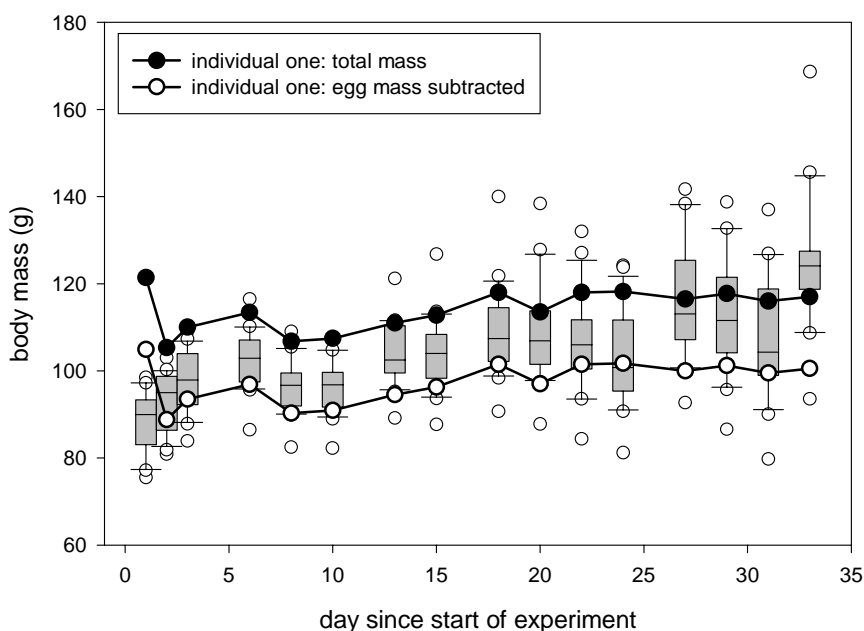
### DISCUSSION

Rather than being a problem resulting from captivity, the swelling in the Turnstone's abdomen was an old egg that had not reached maturity. The egg was smaller than the normal size of Turnstone eggs ( $41 \times 29$  mm; Cramp & Simmons 1983), and there was no sign of a hardened eggshell. The contents were largely solid, implying the egg had been there for some time and gone rotten. The vein of dark material in the egg suggests it was fertilised, so the egg had probably been in the oviduct since the breeding season in June. As egg-laying in the Baltic region (the probable source of



**Fig. 1.** Solidified egg mass in the abdomen of a Ruddy Turnstone in November 2003. (A) Opened abdomen showing the large, round egg in the opened abdomen. (B) Egg and oviduct removed from the bird. The scale on the ruler is in mm. Photos: Jeroen Reneerkens.





**Fig. 2.** Comparison of body masses of individual one and other Turnstones in captivity. Individual one's total body mass, and body mass with the mass of egg and oviduct (16.5 g) subtracted, are shown as circles joined by lines. Box plots summarise the body masses for the other 17 birds (boxes enclose the 25%, 50% and 75% quartiles, whiskers denote the 10th and 90th percentiles, and outliers are shown as small hollow circles).

Wadden Sea birds; Speek and Speek 1985) starts on average from 31 May (Denmark), 7 June (Gulf of Bothnia) to 13 June (Finnmark) (Glutz von Blotzheim *et al.* 1977), it is likely that the egg had been in the abdomen of the bird for up to five months. The smaller thickenings in the oviduct may well have been other developing eggs.

Egg-binding, where an egg becomes stuck in the oviduct, is common, especially in cage-birds. Causes include low levels of vitamins A and E as well as selenium and calcium. Low levels of vitamin A can lead to thickening of the mucosal epithelium of the oviduct and thickened mucus, while deficiencies of vitamin A, selenium and calcium can result in poor muscle tone (Olsen & Orosz 2000). As a consequence the egg is unable to be moved along the oviduct.

In wild birds, egg-binding is often associated with secondary infections that kill the bird, or if the egg is still present during the next breeding season, egg impaction may occur when more eggs enter the oviduct and result in death. If the eggs ruptures into the abdomen, peritonitis can set in and lethal secondary infections can occur. Our individual survived despite the egg in its abdomen, had migrated to the non-breeding grounds, was not starving and could still eat and defecate. However, there was apparently a physiological cost involved in retaining this reproductive material. This Turnstone was the only bird in the sample that had not undergone any moult before capture, and was the only bird that did not then initiate or carry on moult of different feather groups in captivity. The likely cause of the delayed or skipped moult was a secondary infection, though costs of carrying 16.5 g of extra weight may also have been involved. Retarded moult in a poor condition Turnstone was recorded by Underhill (2002), who noted similar findings for an injured Bristle-thighed Curlew *Numenius tahitiensis* (Marks & Underhill 1994) and two parasite-infected Red Knots *Calidris canutus* (Underhill *et al.* 1994).

While the cause of the swelling in the abdomen was identified readily and was not due to the experimental circum-

stances, it is something of a mystery why the apparent growth was not noticed earlier. B.S. swears that the swelling was not present when the bird was caught, but the condition of the egg suggests that it had remained from the breeding season. As the oviduct itself was solidified, the egg itself is unlikely to have moved along it. A possibility is that changes in the size of the digestive organs or general body condition changed the layout of the abdomen, so that the egg mass was further up under the sternum when caught.

## ACKNOWLEDGEMENTS

Thanks to the Stichting Calidris wader-ringing group for catching most of the Turnstones, Brett Gartrell (Institute of Veterinary and Biomedical Sciences, Massey University) for information, and Humphrey Sitters and Sue Moore for useful comments.

## REFERENCES

- Cramp, S. & Simmons, K.E.L. (eds). 1983. Birds of the Western Palearctic, Volume III: Waders to Gulls. Oxford University Press, Oxford.
- Glutz von Blotzheim, U.N., Bauer, K.M. & Bezzel, E. (eds). 1977. Handbuch der Vögel Mitteleuropas, volume 7, Charadriiformes (2. Teil). Akademische Verlagsgesellschaft, Wiesbaden.
- Marks, J.S. & Underhill, L.G. 1994. Molt, mass and migration of a handicapped Bristle-thighed Curlew. *Ardea* 82: 153–156.
- Olsen, G.H. & Orosz, S.E. (eds). 2000. Manual of Avian Medicine. St. Louis, Mosby Inc.
- Speek, B.J. & Speek G. 1985. *Thieme's vogelrekatlas*. Thieme & Cie, Zutphen.
- Underhill, L.G. 2002. A handicapped Ruddy Turnstone *Arenaria interpres* loses mass and delays primary moult. *Wader Study Group Bull.* 98: 44–45.
- Underhill, L.G., Earlé, R.A., Piersma, T., Tulp, I. & Verster, A. 1994. Knots (*Calidris canutus*) from Germany and South Africa parasitized by trematode *Cyclocoelum mutabile*. *Journal für Ornithologie* 135: 236–239.

